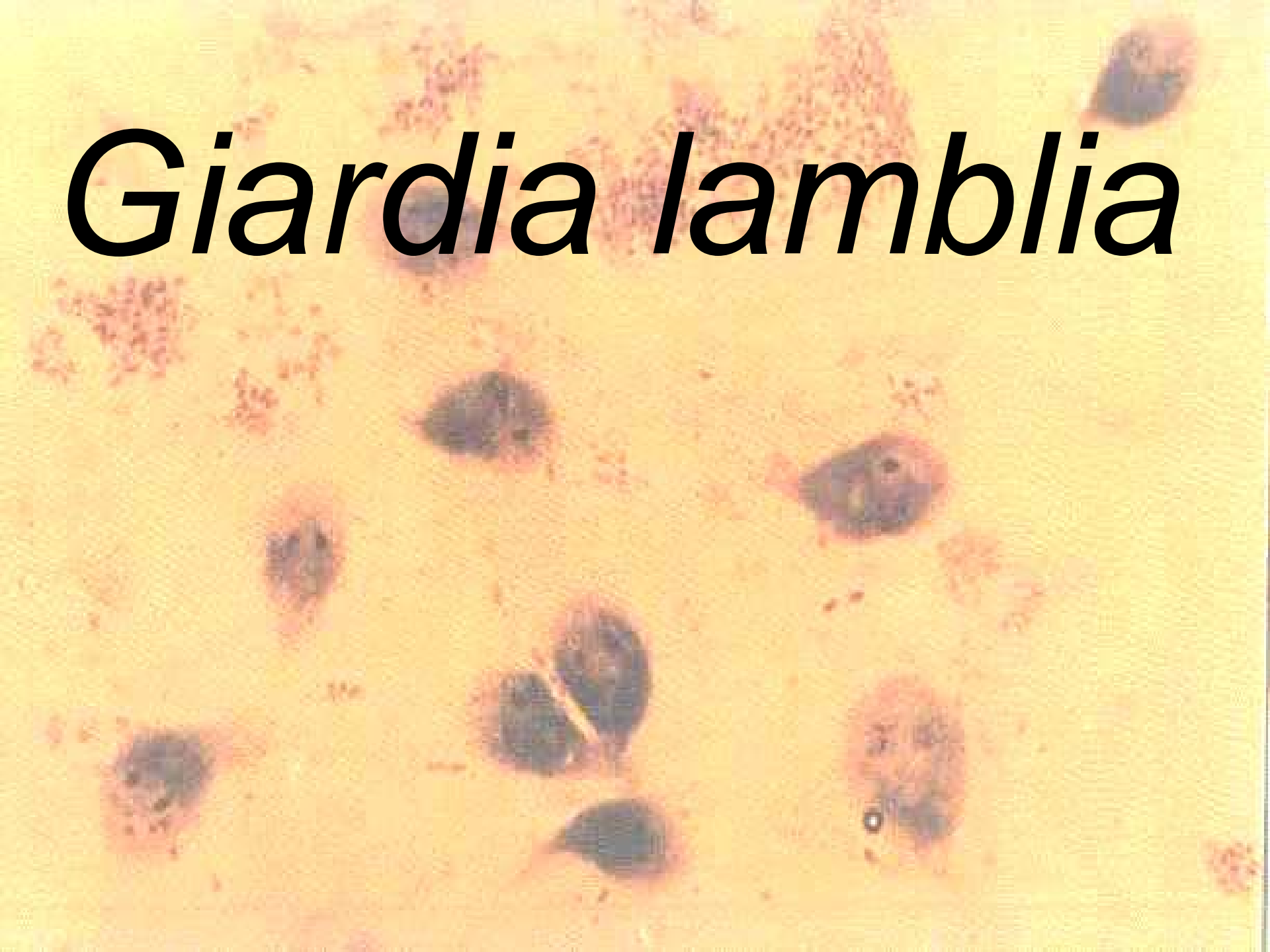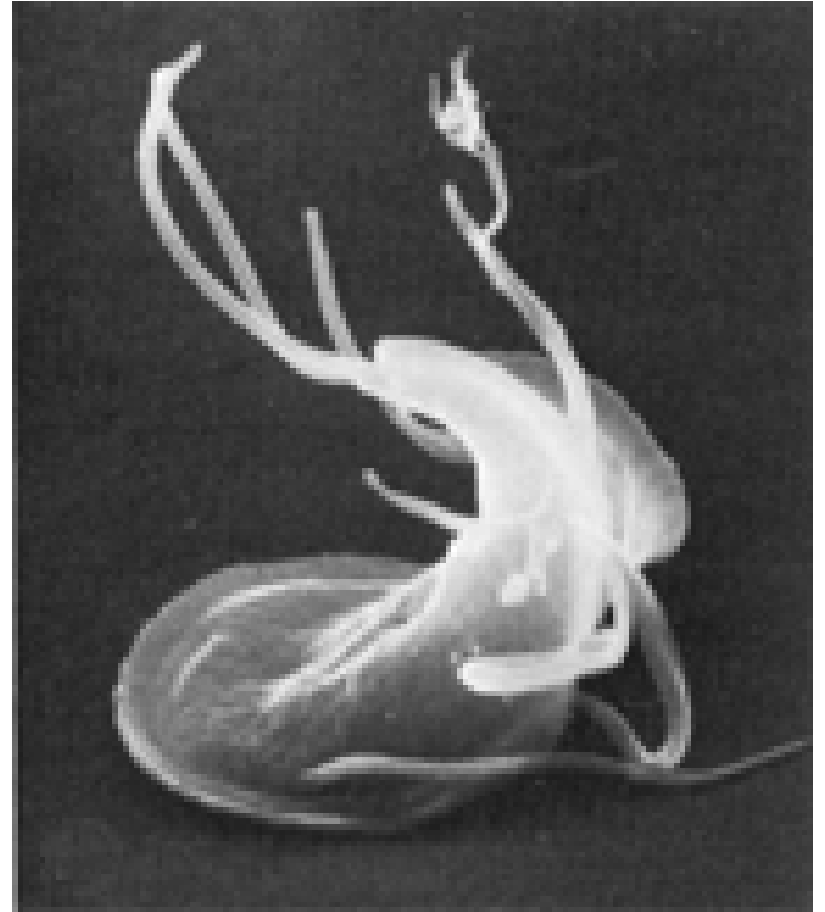


Giardia lamblia



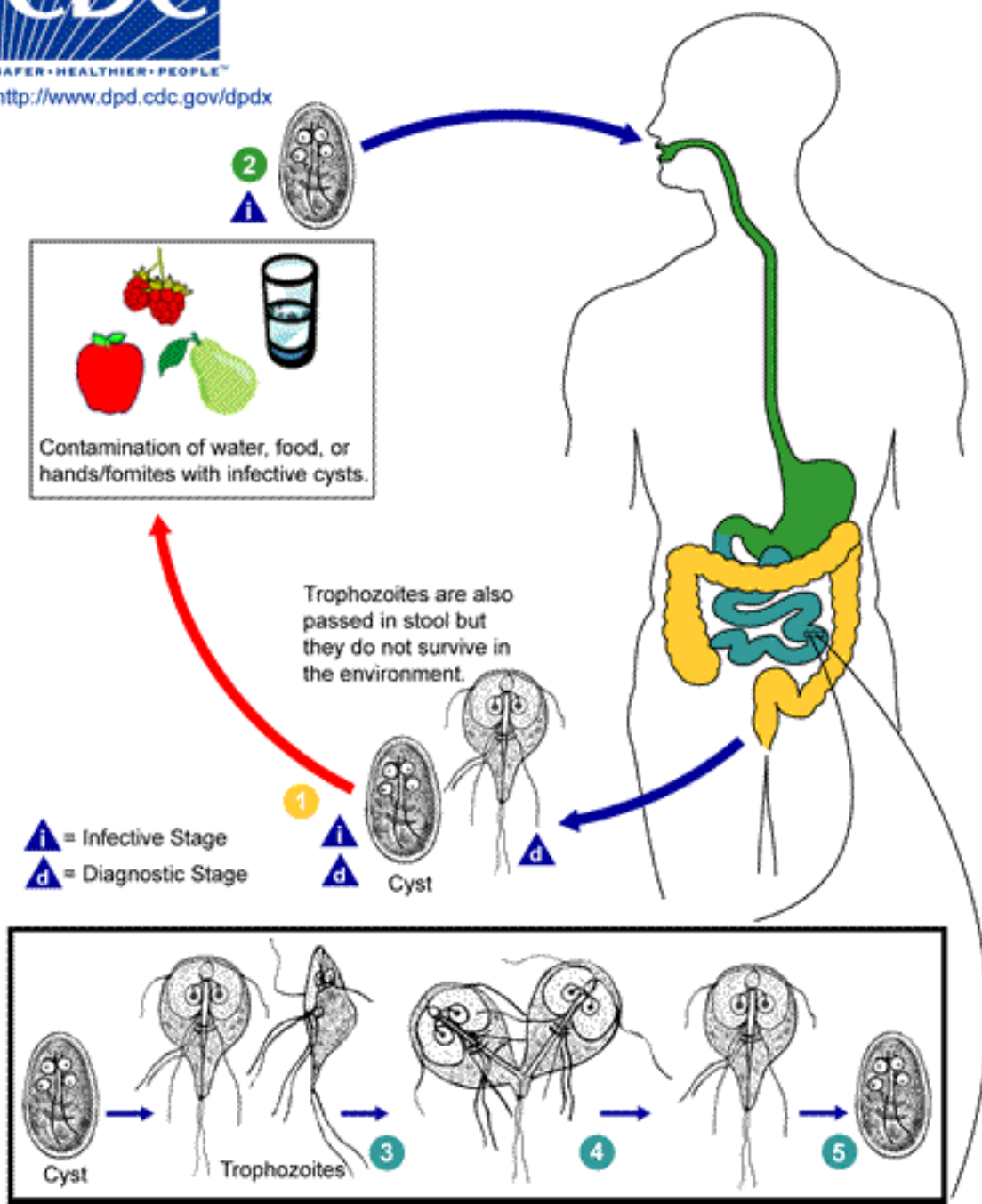
Morphology

- Trophozoite is pear-shaped and measures 12-15 microns
- Cyst is oval and measures 10-20 microns



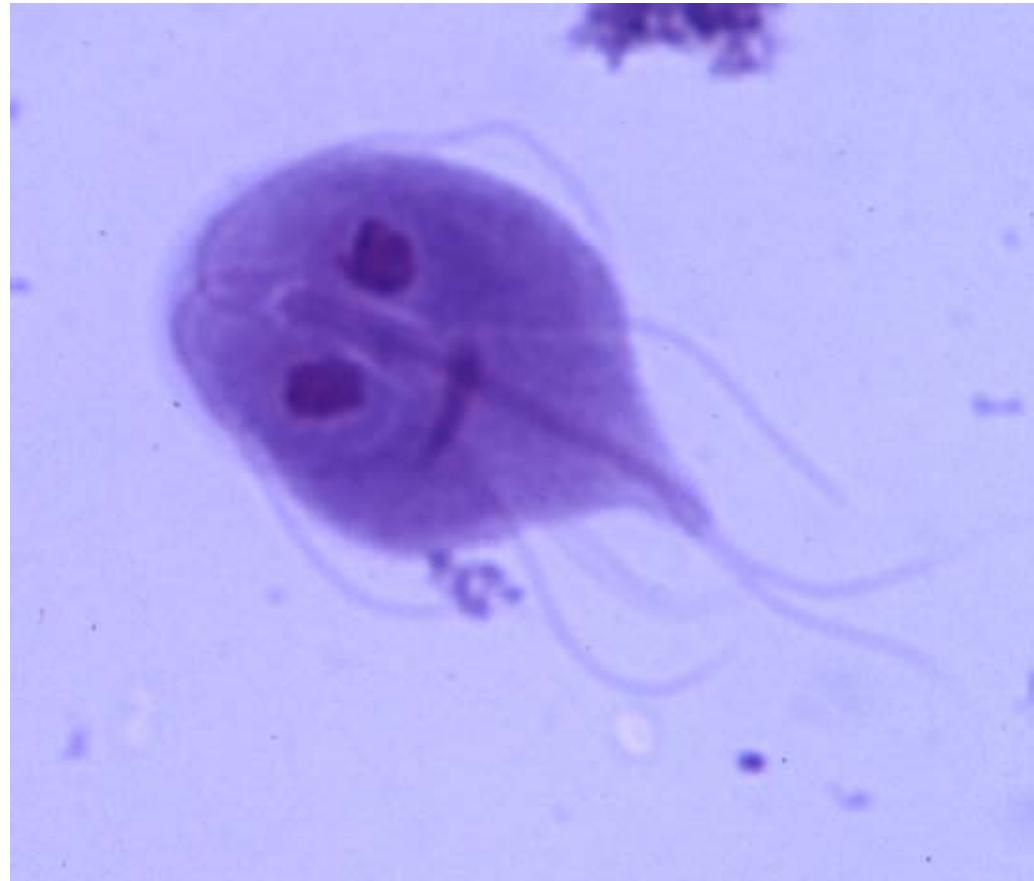Life Cycle

- Cysts ingested by man reach duodenum and multiply (100 or more cysts ingested results in 100% infection)
- Infective cysts are usually passed in stool and trophozoites are seen only in diarrheal states



Epidemiology

- Worldwide
- More common in warm climates



Diagnosis

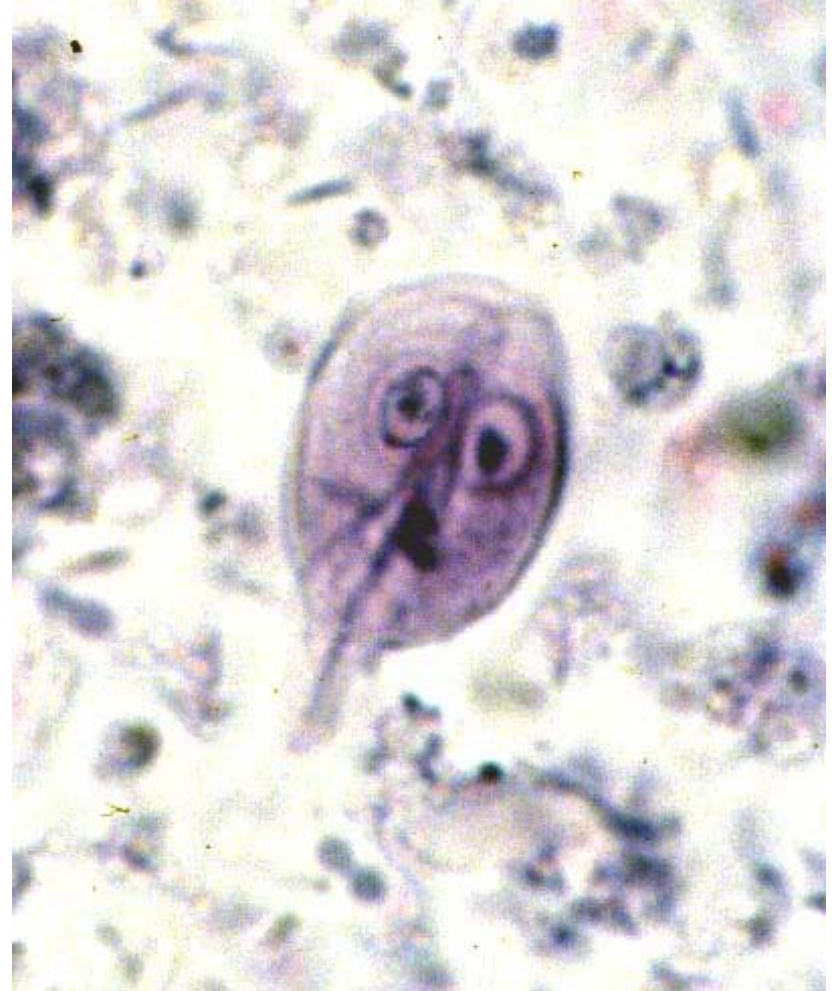- Stool exam
- Duodenal aspirate
- Occasionally by small bowel biopsy

Symptomatology

- Most often asymptomatic or mild abdominal symptoms
- Diarrhea with or without malabsorption in children
- Patients with intestinal lymphangiectasia, pancreatitis, achlorhydria, gastrectomy, are more prone to overt symptoms
- Occasionally symptoms mimicking biliary disease
- In adults, diarrhea alternates with constipation

Treatment

- Quinacrine (Atabrine)
- Metronidazole (Flagyl)



Prevention

- Sanitary disposal of feces
- Examination of food handlers
- Protection of water supplies from contamination
- Avoid consumption of raw foods or unprocessed water in highly endemic areas